

# Corneal intrastromal implantation surgery for the treatment of moderate and high myopia

Albert Daxer, MD, PhD

I describe a corneal intrastromal implantation technique that uses a new type of microkeratome to create a closed intrastromal pocket as well as a continuous ring-shaped inlay with shape memory for placement in the pocket. The technique is a minimally invasive way to treat patients with moderate and high myopia. It can be considered an alternative to laser in situ keratomileusis and phakic intraocular lens implantation in these cases. The technique can be performed quickly and easily and appears safe and effective.

*J Cataract Refract Surg* 2008; 34:194–198 © 2008 ASCRS and ESCRS

Laser in situ keratomileusis (LASIK) is considered a risk factor for biomechanical instability of the cornea, particularly in eyes with moderate and high myopia.<sup>1</sup> Therefore, clear lens extraction and phakic intraocular lens (pIOL) implantation are currently the treatments of choice for moderate and high myopia by most refractive surgeons.<sup>2</sup> However, pIOL implantation may be accompanied by serious complications, including cataract formation, endophthalmitis, and endothelial decompensation,<sup>2</sup> and implanting corneal ring segments in a circular tunnel of the corneal stroma is limited to myopia of less than 6.0 diopters (D).<sup>3,4</sup> I describe a new technology that is based on corneal intrastromal implantation surgery (CISIS) as a possible alternative for the treatment of low, moderate, and high myopia.

## SURGICAL TECHNIQUE

The surgical procedure starts with the creation of a pocket within the corneal stroma with the new PocketMaker microkeratome (Dioptex GmbH). The diameter of the pocket is preferably 9.0 mm and the depth, 300  $\mu\text{m}$ . Except for a 3.0 mm wide and

2.0 mm long incision tunnel, which is preferably located in the temporal periphery of the cornea, the pocket is closed along the entire circumference. The microkeratome consists of a suction ring, an applicator with a guiding mean for the handpiece, a handpiece (Figure 1) containing a motor-driven blade that vibrates in the cutting plane, a control unit, and a disposable transparent applanator. After the applicator is fixated to the eye by the suction ring, the disposable transparent applanator is introduced into the applicator. The applanation and cutting process is visible to the surgeon via the transparent applanator (Figure 2). The applanator is designed with a magnification lens with the focal point at the cutting plane.

After the closed intrastromal pocket is created via the small incision tunnel and the suction ring is removed from the eye, a continuous and deformable ring implant (MyoRing, Dioptex GmbH) is inserted into the corneal pocket via the small incision tunnel (Figure 3). The depth of the pocket is defined by the dimensions of the applanator. (A 300  $\mu\text{m}$  applanator can be ordered from the company.)

The correct position of the blade must be confirmed before surgery by a test procedure in which the surgeon compares the position of the blade tip when inserted into the applicator with a scale on a measuring gauge in the applicator. The test must be performed under a surgical microscope.

The implant is made of poly(methyl methacrylate). The dimensions depend on the refractive "power." The diameter ranges from 5.0 to 8.0 mm and the thickness, from 150 to 350  $\mu\text{m}$ ; the width of the ring is 0.5 mm. The anterior surface is convex and the posterior surface concave, with a radius of curvature of 8.0 mm. The particular shape and dimensions permit folding, which makes implantation in the pocket via the small

Accepted for publication October 25, 2007.

From the Eye Center, Linz, and the Department of Ophthalmology of the Medical University of Innsbruck, Innsbruck, Austria.

The author has a financial interest.

Presented in part at the ASCRS Symposium on Cataract, IOL and Refractive Surgery, San Diego, California, USA, April 2007, and the XXV Congress of the European Society of Cataract and Refractive Surgeons, Stockholm, Sweden, September 2007.

Corresponding author: Dr. Albert Daxer, Landstrasse 68, A-4020 Linz, Austria. E-mail: daxer@gutsehen.at.

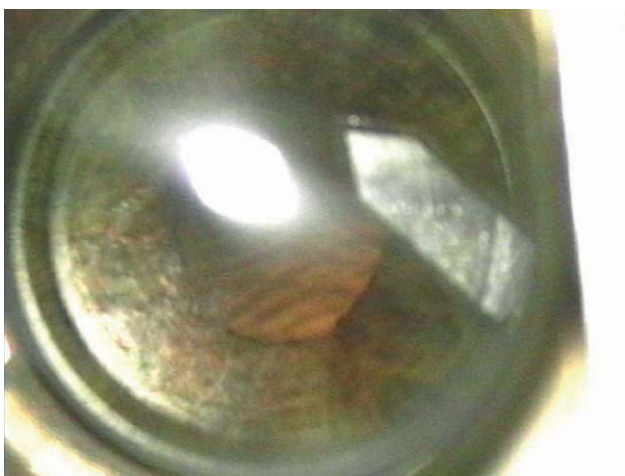

**Figure 1.** The PocketMaker microkeratome.

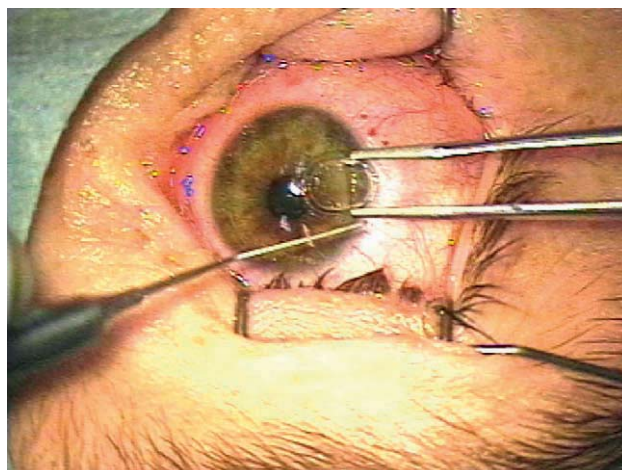
incision tunnel possible. The implantation procedure is performed with an implantation forceps. Centering the implant in the pocket can be performed by an adequate hook or a forceps. The incision tunnel is self-sealing and does not require suturing.

Removing the MyoRing from the intracorneal pocket can be done quickly and easily, requiring a spatula to reopen the pocket and a forceps to pull the implant through the small incision. The procedure takes approximately 3 minutes. The pocket closes immediately after the implant is removed.

Antibiotic eyedrops are prescribed 5 times daily during the first 3 days postoperatively. The surgeon has to order a MyoRing with a given Diopter value. The PocketMaker microkeratome and the MyoRing intracorneal implant have CE marking and are approved for surgery in the European Union.



**Figure 2.** View through the transparent applanator of the PocketMaker microkeratome during formation of the pocket.

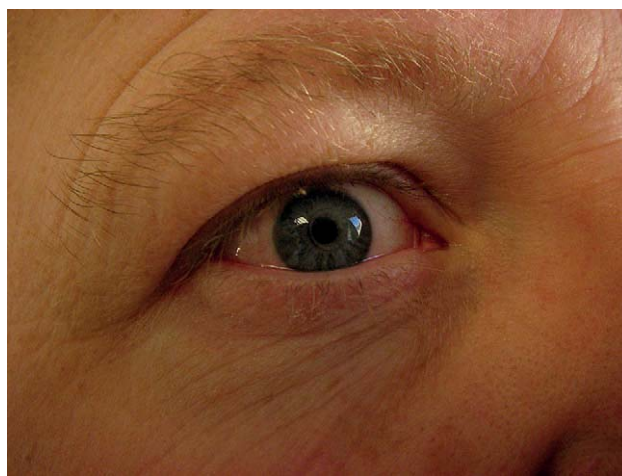

**Figure 3.** Insertion of the MyoRing into the corneal pocket through the small incision tunnel. Note the change in the shape of the ring during implantation.

#### Clinical Data

Figure 4 shows a MyoRing in situ in the right eye of a 38-year-old man 3 months after implantation. Cosmetically, the implant appears similar to a hard contact lens. The preoperative refraction was  $-13.50 -3.00 \times 175$ . The CISIS procedure was performed and a 14.0 D MyoRing implanted. Two weeks postoperatively, the eye was emmetropic and the uncorrected visual acuity was 1 line better than the best corrected visual acuity before surgery. The patient is very satisfied and has not reported daytime or nighttime problems.

Figure 5 is a 3-day postoperative slitlamp photograph of the right eye of a 43-year-old woman who was treated for myopia of  $-18.00$  D.



**Figure 4.** Appearance of the MyoRing in situ.



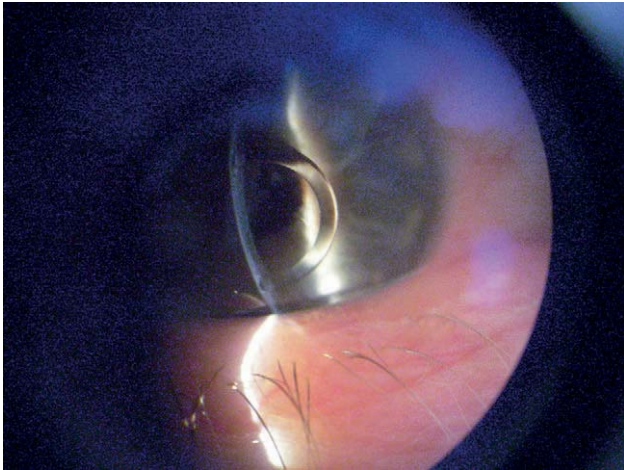


Figure 5. Slitlamp photograph 3 days after MyoRing implantation.

Figure 6 shows the right eye of a 35-year-old woman 1 day after removal of a MyoRing. The preoperative refraction was  $-13.00 -0.75 \times 30$ . The removal was done 10 weeks after implantation because of residual myopia. A clinically insignificant demarcation line is seen at the former position of the implant (*arrow*). The line is the result of both, reversible local compression of the tissue at the site of the implant and debris. The latter results from the insertion process. Irrigating the pocket after implantation can prevent the collection of debris in this area. After the implant was removed, the patient wore her old contact lenses without loss of visual acuity or comfort.

Figure 7 is a vertical Scheimpflug (Pentacam, Oculus GmbH) cut through the cornea of the right eye of a 46-year-old woman 3 days after MyoRing implantation for myopia of  $-9.0$  D. Figure 8 shows the corneal

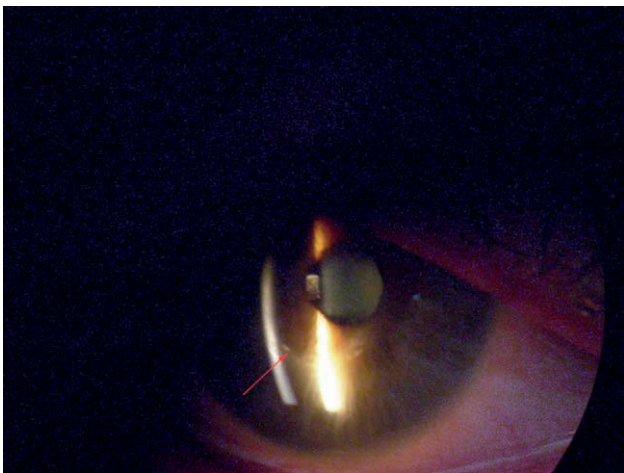


Figure 6. Slitlamp photograph 1 day after removal of the MyoRing, showing a fine demarcation line in the stroma (*arrow*) where the implant was placed.

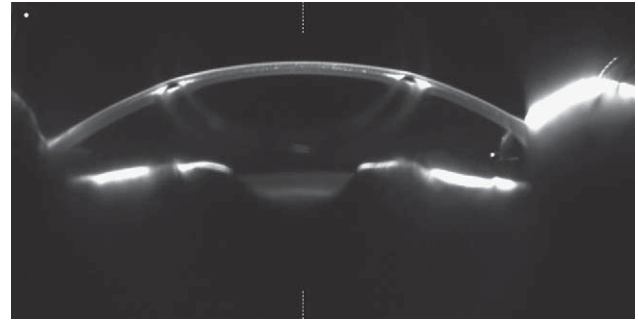
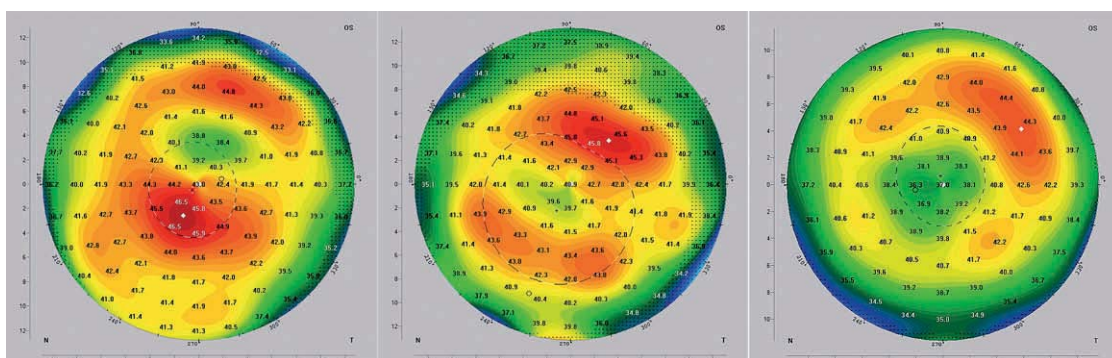


Figure 7. A vertical Scheimpflug cut through the cornea 3 days after MyoRing implantation.

topography before surgery (*left*), 15 minutes after surgery (*middle*), and 3 days after surgery (*right*) in the left eye of a 23-year-old man with myopia of  $-14.00 -4.00 \times 90$ . There was no clinical sign of keratoconus preoperatively. The Pentacam keratoconus detection system classified the preoperative situation as borderline between normal and grade 1. The pachymetry and pachymetry distribution were within the normal range. The situation was probably mild forme fruste keratoconus. The changes in corneal topography demonstrate that astigmatism of up to at least 4.0 D can be corrected. They also demonstrate a kind of “regularization” of the corneal surface.

## DISCUSSION

As seen from the clinical data, this technique has the potential to correct significant myopic as well as astigmatic refractive errors. Introducing the implant into the intracorneal pocket changes the shape of the entire cornea in a way that generates a new equilibrium for the shape of the cornea, resulting in a flatter central cornea. This can be observed in Figure 7, which does not indicate a significant elevation of the corneal tissue over the implant. Corneal intrastromal implantation surgery also seems to improve the geometry of the optically relevant central corneal surface into a generally regular shape. This behavior can be explained by topology, which considers that many important mathematical processes depend on the properties of limit points.<sup>5</sup> According to this theory, every point of the cornea that is spanned inside a regular continuous ring is determined within the ring. The shape of the cornea within the circumference of the MyoRing is therefore the result of an equilibrium that depends on the regularity of the circumference of the implant. This mechanism explains not only the correction of regular astigmatism but also the elimination of sources of higher-order aberrations (HOAs), illustrated in Figure 8. It appears that this technology is promising for cases of keratoconus.



**Figure 8.** Corneal topography of the same eye before MyoRing implantation (*left*), immediately postoperatively (*middle*), and 3 days postoperatively (*right*).

One limitation of the technique is pupil size. To prevent glare and problems with night vision, the manufacturer of CISIS devices recommends that the MyoRing diameter not extend the mesopic pupil size.

The concept of adding volume to the corneal periphery instead of removing tissue from the center of the cornea for myopia correction was first established in the 1990s.<sup>6</sup> It offers a high grade of safety and reversibility.<sup>3,4</sup> Placing the implant in a pocket has the additional advantage that the implant can be centered or recentered simply by moving it inside the pocket to the right position with a forceps or hook. This allows optimization of the optical properties.

The results demonstrate that the procedure is reversible and that removing the implant does not result in a detectable change in the refraction relative to the preoperative status or in a significant alteration of the corneal tissue. After the implant was removed, the patient was able to wear the former contact lenses without changes in the refraction or shape of the lens.

One significant advantage of the technique is that it neither alters the biomechanics of the cornea nor requires intraocular surgery. The corneal stroma consists of 200 lamellae of liquid-crystal-like arranged, proteoglycan-coated collagen fibrils.<sup>7</sup> Within each lamella, the proteoglycan-coated collagen fibrils run parallel to each other and the lamellae of the normal corneal stroma show preferred orientation along 2 orthogonal directions.<sup>8</sup> The internal construction of the stroma determines the nutritional function, transparency, shape, and biomechanical stability of the tissue. Specifically, the arrangement of the collagen fibrils creates a biomechanical framework and changes in the structural elements may have a significant impact on the function of the cornea.<sup>9</sup>

The biomechanical stability of the cornea is characterized by the ability to withstand the forces resulting from the difference between intraocular pressure (IOP) and external pressure. These forces generate tension within the cornea that has to be compensated by the

tissue to preserve the cornea's shape and, therefore, the cornea's optical function. The tension lines run along the orientation of the collagen fibrils, and the biomechanical cross-sectional area relevant for withstanding the forces is roughly proportional to the sum of the cross-sectional areas of the collagen fibrils across the entire thickness of the corneal stroma.

Although recent reports suggest a relatively low incidence of keratectasia in patients with moderate and high myopia treated with LASIK,<sup>10</sup> reducing the number of collagen fibrils by cutting a significant number of them via a LASIK flap must reduce the biomechanical stability of the tissue.<sup>11</sup> This means that a LASIK-thinned cornea has a reduced ability to withstand an unfavorable relationship between IOP and external pressure. This can be considered a negative factor for adaptation to significant pressure changes by LASIK patients. These patients may also experience visual disturbances from HOAs less severe than keratectasia; however, related studies are not available. Since the PocketMaker microkeratome generates the intrastromal pocket by cutting parallel to the collagen fibrils, in contrast to a LASIK microkeratome, without a peripheral cut through (perpendicular to) the fibrils, weakening of the cornea's biomechanics is not expected in CISIS.

The CISIS technique is easy to perform and appears to be safe and effective for the treatment of moderate and high myopia. Long-term follow-up is, however, mandatory to verify the safety and efficacy of the outcome.

## REFERENCES

1. Randleman JB, Russell B, Ward MA, et al. Risk factors and prognosis for corneal ectasia after LASIK. *Ophthalmology* 2003; 110:267–275
2. Lovisolo CF, Reinstein DZ. Phakic intraocular lenses. *Surv Ophthalmol* 2005; 50:549–587
3. Ruckhofer J, Stoiber J, Alzner E, Grabner G. One year results of European multicenter study of intrastromal corneal ring segments. Part 1: refractive outcomes; the Multicenter European

- Corneal Correction Assessment Study Group. J Cataract Refract Surg 2001; 27:277–286
4. Schanzlin DJ, Abbott RL, Asbell PA, et al. Two-year outcomes of intrastromal corneal ring segments for the correction of myopia. Ophthalmology 2001; 108:1688–1694
  5. Hocking JG, Young GS. Topology. New York, NY, Dover, 1988
  6. Nosé W, Neves RA, Schanzlin DJ, Belfort R Jr. Intrastromal corneal ring—one-year results of first implants in humans: a preliminary nonfunctional eye study. Refract Corneal Surg 1993; 9:452–458
  7. Fratzi P, Daxer A. Structural transformation of collagen fibrils in corneal stroma during drying; an x-ray scattering study. Biophys J 1993; 64:1210–1214. Available at: <http://www.biophysj.org/cgi/reprint/64/4/1210>. Accessed November 5, 2007
  8. Daxer A, Misof K, Grabner B, et al. Collagen fibrils in the human corneal stroma: structure and aging. Invest Ophthalmol Vis Sci 1998; 39:644–648
  9. Daxer A, Fratzi P. Collagen fibril orientation in the human corneal stroma and its implication in keratoconus. Invest Ophthalmol Vis Sci 1997; 38:121–129
  10. Condon PI, O’Keefe M, Binder PS. Long-term results of laser in situ keratomileusis for high myopia: risk of ectasia. J Cataract Refract Surg 2007; 33:583–590
  11. Ortiz D, Piñero D, Shabayek MH, et al. Corneal biomechanical properties in normal, post-laser in situ keratomileusis, and keratoconic eyes. J Cataract Refract Surg 2007; 33:1371–1375



First author:  
Albert Daxer, MD, PhD

*Eye Center, Linz, and the Department of  
Ophthalmology of the Medical University  
of Innsbruck, Innsbruck, Austria*