

Implantation of a Complete Corneal Ring in an Intrastromal Pocket for Keratoconus

Haifa Mahmood, MD; R.S. Venkateswaran, OD; Albert Daxer, MD, PhD

ABSTRACT

PURPOSE: To evaluate the refractive and visual results of a new treatment for keratoconus using the corneal intrastromal implantation system (CISIS).

METHODS: Six eyes of four patients with keratoconus were treated with CISIS. Follow-up was 1, 3, and 6 months. After creating an intracorneal pocket of 9-mm diameter and 300- μ m depth, a flexible full-ring implant was inserted via a 4-mm-wide corneal tunnel.

RESULTS: No eyes showed loss of lines in uncorrected distance visual acuity (UDVA) or spectacle corrected distance visual acuity (CDVA) at any follow-up examination. Uncorrected and distance corrected visual acuity, keratometry, spherical and cylindrical refractive error as well as spherical equivalent refraction improved significantly ($P < .05$). Mean UDVA improved from 20/260 to 20/48 and mean CDVA improved from 20/41 to 20/27. A significant centralization and decrease of the corneal apex was found. No intra- or postoperative complications were observed.

CONCLUSIONS: The corneal intrastromal implantation system using a complete ring implanted in a stromal pocket can achieve significant improvements in the visual function of patients with keratoconus. Uncorrected distance visual acuity improved by more than seven lines on average and CDVA improved by two lines. [*J Refract Surg.* 2010;xx:xxx-xxx.]

doi:10.3928/1081597X-20100212-11

Keratoconus is a corneal disease characterized by progressive thinning and ectasia of the cornea.¹ Ultrastructural changes of the collagen matrix play an important role in the related biomechanical weakening of the tissue.² Implantation of corneal ring segments into a circular corneal tunnel improves visual acuity and reduces central corneal steepening in keratoconus.³⁻¹¹ A new surgical system referred to as the corneal intrastromal implantation system (CISIS™, DIOPTEx GmbH, Linz, Austria), where the MyoRing flexible full-ring implant (DIOPTEx GmbH) is inserted into a corneal pocket, proved effective in the treatment of high myopia and keratoconus.^{12,13} The purpose of this study is to evaluate whether CISIS treatment can achieve a significant improvement in the visual function of patients with keratoconus.

PATIENTS AND METHODS

No ethics approval was needed as both the MyoRing and PocketMaker have CE marking and are approved in Europe as medical devices for the surgical treatment of keratoconus and myopia.

Six eyes of four patients (two men, two women) with keratoconus were treated by CISIS involving implantation of MyoRing intracorneal rings into a corneal pocket created by the PocketMaker microkeratome (DIOPTEx GmbH). Informed

From Dr Haifa Mahmood Eye Specialist Center, Manama, Kingdom of Bahrain (Mahmood, Venkateswaran); Daxer Eye Center, Ybbs-Linz, and the Department of Ophthalmology, Medical University of Innsbruck, Innsbruck, Austria (Daxer).

Dr Daxer has a financial interest and owns stock in DIOPTEx GmbH, Linz, Austria. Drs Mahmood and Venkateswaran have no financial interest in the materials presented herein.

Data previously presented at the MNTK Conference, October 2008, Moscow, Germany; Middle East African Council of Ophthalmology Congress, March 26-30, 2009, Manama, Bahrain; and American Society of Cataract and Refractive Surgery meeting, April 3-8, 2009, San Francisco, Calif.

Correspondence: Albert Daxer, MD, PhD, Eye Center Ybbs-Linz, Stauwerkstrasse 1, A-3370 Ybbs, Austria. Tel: 43 7412 53110; Fax: 43 7412 5311020; E-mail: daxer@gutsehen.at

Received: March 5, 2009; Accepted: January 21, 2010

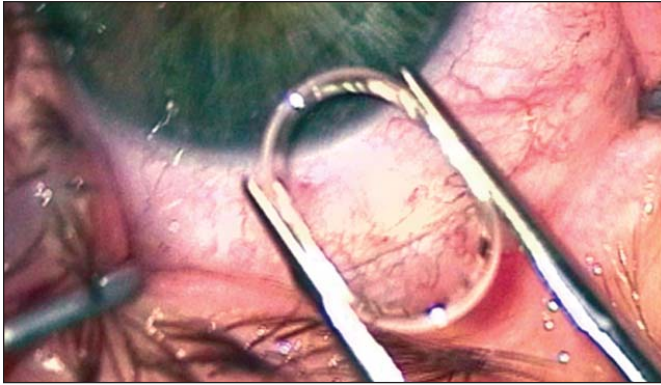


Figure 1. The MyoRing intracorneal implant (DIOPTEx GmbH) compressed by implantation forceps for implantation into the corneal pocket, as seen through the surgical microscope during surgery.

consent was obtained from all patients and included explanation of all possible options of treatment. Patients were randomly chosen without accounting for any particular inclusion criteria, except corneal clarity and central corneal thickness $\geq 350 \mu\text{m}$. A particular mesopic pupil size was not considered an inclusion or exclusion criterion.

Compared to conventional corneal ring segment surgery (Intacs [Addition Technologies, Des Plaines, Ill], Ferrara Ring and KeraRing [Mediphacos, Belo Horizonte, Brazil]), where one or two ring segments of particular arc length are inserted into a circular corneal tunnel to avoid touching the corneal center, the new procedure described herein follows a different concept.

The MyoRing is a full-ring implant, which is available in a diameter range of 5 to 8 mm and a thickness range of 200 to 400 μm in 20- μm increments. The width of the ring body is 0.5 mm. The implant can be inserted into a closed corneal pocket (“inverse flap”) via a small corneal tunnel of $< 4 \text{ mm}$ by compressing the implant in one dimension (Fig 1). Although the MyoRing is made of polymethylmethacrylate, its particular design allows significant compression without the risk of breakage. Once placed into the pocket, the MyoRing inflates to its original preoperative shape. After implantation, the cornea adopts a modified shape resulting from a new biomechanical equilibrium. The PocketMaker microkeratome (Fig 2) for the creation of the closed corneal pocket, into which the MyoRing implant is to be placed, consists of an ultra-thin and micron-guided diamond blade, which is set in microvibration during cutting. The diamond blade is extremely sharp to facilitate a precise, smooth, and atraumatic preparation of the pocket. Because the opening of the pocket (tunnel) is self-sealing, the procedure does not require suturing. The surgical technique is described in more detail elsewhere.^{12,13}

Statistical analysis of the preoperative versus 6-month




Figure 2. The PocketMaker microkeratome (DIOPTEx GmbH).

postoperative data was performed by paired two-tailed *t* test of uncorrected distance visual acuity (UDVA [logMAR]), spectacle corrected distance visual acuity (CDVA [logMAR]), average keratometry with $K=(K_1+K_2)/2$ obtained from the 3-mm zone, refractive spherical equivalent (SE), and spherical and cylindrical component of the refractive error. If not indicated otherwise, statistical measures are mean \pm standard deviation and differences between mean values are considered statistically significant when $P < .05$. Follow-up was 1, 3, and 6 months. None of the eyes underwent an enhancement procedure (optimization of the implant position) as described previously.¹³

Two eyes were treated with corneal cross-linking (CXL) 2 months prior to surgery. Preoperative data of these eyes were obtained immediately before CISIS, showing a clear cornea. The nomogram considered in this study uses a MyoRing with a diameter of 5 mm and a thickness depending on the K value. A thickness of 280 μm is chosen when $K \geq 50.00$ diopters (D) and 240 μm when $K < 50.00$ D. According to this nomogram, CXL as a pre-treatment prior to CISIS is optional when $K > 50.00$ D and recommended when $K \geq 55.00$ D. Uncorrected and corrected distance visual acuity were converted into a logarithmic scale (logMAR) before statistical analysis. The mean value was converted back to 20/20 notation. The standard deviation is given only in logMAR. The data represent a small retrospective case series.

RESULTS

Pre- and postoperative data are presented in Tables 1 and 2, respectively. Each individual eye showed an improvement of all parameters (UDVA, CDVA, keratometry, SE, sphere, cylinder) during each follow-up examination compared to the preoperative measurements (Fig 3). The improvement between the preoperative values and the 6-month postoperative data was statistically significant ($P < .05$) for UDVA, CDVA, keratometry, SE, sphere, and cylinder. Preoperatively, five of six eyes had UCVA of 20/200 or worse, whereas after 3 and 6 months, four of six eyes had UCVA of

TABLE 1

Preoperative Characteristics of Six Eyes That Underwent the Corneal Intrastromal Implantation System With MyoRing Implantation

Case	Age (y)	CCT (μm)	Sphere (D)	Cylinder (D)	Axis ($^{\circ}$)	UDVA	CDVA	K1 (D)	K2 (D)	K (D)
1*	26	350	-6.00	-2.50	140	20/400	20/40	54.98	52.45	53.71
2	22	366	-4.50	-3.00	50	20/400	20/30	50.87	49.6	50.23
3	22	408	-3.00	-4.00	80	20/200	20/40	48.14	45.07	46.60
4*	33	411	-9.50	-4.50	10	20/400	20/40	59.77	53.66	56.71
5	27	462	-8.00	-2.25	100	20/200	20/40	49.17	46.30	47.74
6	27	477	-6.00	-2.75	150	20/125	20/30	49.44	48.02	48.73

CCT = central corneal thickness, UDVA = uncorrected distance visual acuity, CDVA = corrected distance visual acuity, K = keratometry
 *Eyes that were treated with corneal cross-linking prior to the corneal intrastromal implantation system.

TABLE 2

6-month Postoperative Results of Six Eyes That Underwent the Corneal Intrastromal Implantation System With MyoRing Implantation

Case	Sphere (D)	Cylinder (D)	Axis ($^{\circ}$)	UDVA	CDVA	K1 (D)	K2 (D)	K(D)
1*	0.00	-1.50	150	20/40	20/30	42.34	34.75	38.54
2	-0.25	-0.75	60	20/35	20/30	46.87	42.88	44.87
3	0.50	-0.50	140	20/35	20/30	42.59	40.34	41.46
4*	-3.25	-0.75	150	20/100	20/30	48.93	46.02	47.47
5	-2.00	-1.00	60	20/40	20/20	42.73	38.23	40.48
6	0.75	-2.00	10	20/60	20/30	42.20	40.38	41.29

UDVA = uncorrected distance visual acuity, CDVA = corrected distance visual acuity, K = keratometry
 *Eyes that were treated with corneal cross-linking prior to the corneal intrastromal implantation system.

20/40 or better. Mean UDVA improved by more than seven lines from 20/260 (1.113 ± 0.22 logMAR) to 20/48 (0.383 ± 0.186 logMAR). The improvement in mean CDVA was approximately two lines from 20/41 (0.315 ± 0.113 logMAR) to 20/27 (0.142 ± 0.069 logMAR).

No intra- or postoperative complications were observed. One patient reported glare symptoms, but clinical significance was not sufficient to warrant repositioning, replacement, or removal of the implant. Figure 4 shows an eye with the MyoRing. Figure 5 shows the pre-/postoperative tangential topography maps of all eyes. Because the tangential map represents the local curvature, it recognizes sharp power transitions more readily and is therefore better suited for identifying the implant position (see Fig 5, red circles in the postoperative images) than an axial map. An analysis of the position of the corneal apex of the five non-central cases (case 4 is excluded) shows significant improvement and regularization of the corneal surface after surgical treatment. Preoperative decentration of the cone (steepest point) was 1.1 ± 0.2 mm and after treat-

ment measured 0.7 ± 0.2 mm in the tangential map. Decentration of the cone was significantly reduced in the non-central cases ($P=.012$).

DISCUSSION

One potential advantage of CISIS is that it allows individualized treatment with access to all three degrees of freedom, ie, ring thickness, ring diameter, and ring position relative to the optical axis.¹³ Of particular interest is the option of repositioning the implant with respect to the optical axis, which may result in additional improvement of visual function.¹³ However, in the presented series of treatments, this "optimizing feature" was not applied, ie, no enhancement through individual positioning of the implants was performed after initial implantation.

The mean improvement in UDVA of more than seven lines is impressive, whereas CDVA results appear similar to those obtained from implantation of ring segments in the corneal stroma.³⁻¹¹ Three eyes had advanced keratoconus with preoperative keratometry

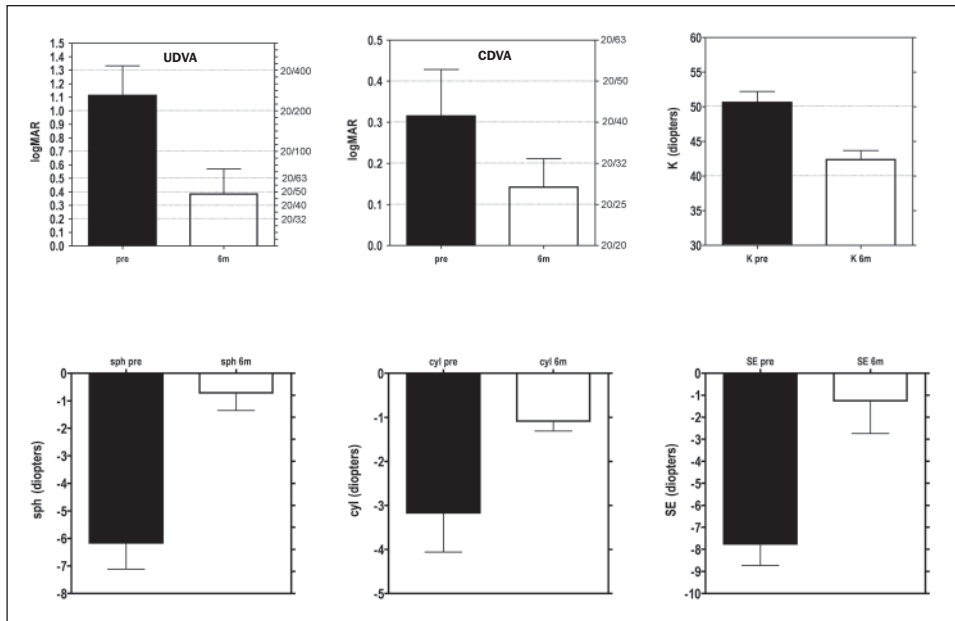


Figure 3. Mean uncorrected distance visual acuity (UDVA), spectacle corrected distance visual acuity (CDVA), keratometry, sphere (sph), cylinder (cyl), and spherical equivalent refraction (SE) preoperatively and 6 months postoperatively. Mean UDVA and CDVA are shown in logMAR (left vertical axis) and in 20/20 scaling (right vertical axis). The error bars represent the standard deviation. In the UDVA and CDVA graphs, the error bars represent the standard deviation in logMAR only.

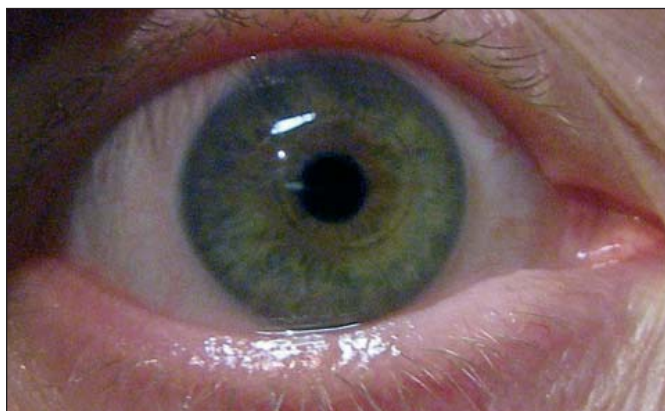

Figure 4. Eye with MyoRing (DIOPTEX GmbH) after implantation.

>50.00 D. In a recent study by Shetty et al⁹ on Intacs treatment in advanced keratoconus cases, which had roughly comparable preoperative pachymetry and K-readings, UDVA improved by five lines from 20/400 to 20/125, whereas CDVA improved from 20/40 to 20/30. The mean reduction in keratometry in the study by Shetty et al⁹ was approximately 3.50 D, compared to approximately 8.00 D in the current study. The fact that CISIS, due to its significant effect on keratometry, strongly impacts the spherical component of the refractive error may be the reason why CISIS proves so efficient in improving UDVA. This is additionally confirmed by the observation that the mean spherical component of the refractive error is reduced by approximately 6.00 D and the SE by almost 7.00 D. This implies that the remaining refractive error after CISIS mainly results from the residual manifest cylindrical component, which also significantly decreases to approxi-

mately 1.00 D after only 6 months. As can be seen from Tables 1 and 2, the difference of K1 and K2 before and after surgery did not change significantly. The same applies to the simulated keratometry (not shown). In certain cases, the absolute value of K2-K1 even increased. Despite an increase of the “topographic cylinder,” all other refractive data improved. The solution can be found in the topographic pattern, which shows a “regularization” of the cornea from a highly irregular cornea to a more regular one (bowtie pattern).¹³ Our results show that in non-central cones, treatment results in significant regularization of the optic zone, which is characterized by a significant ($P<.05$) centralization of the corneal apex.

A limiting factor in the present study is the small number of cases. However, improvements were statistically significant in all statistical tests despite this limitation. Although the small study sample did not affect the significance of the refractive and visual results, this limiting factor may prove of relevance with respect to the probable occurrence of complications. Another limiting factor seems to be the “mixture” of eyes that did and did not undergo CXL. Although there is no evidence demonstrating the length of time for the effect of CXL to complete, the available data suggest that it has no significant impact on the improvement of the refractive results by adding the isolated refractive effect of CXL to that of CISIS. Even in long-term follow-up, CXL has no or only a small refractive effect compared to that of MyoRing implantation.^{14,15} In advanced cases of keratoconus where CXL is applied prior to CISIS, the mechanism of improvement seems to be the

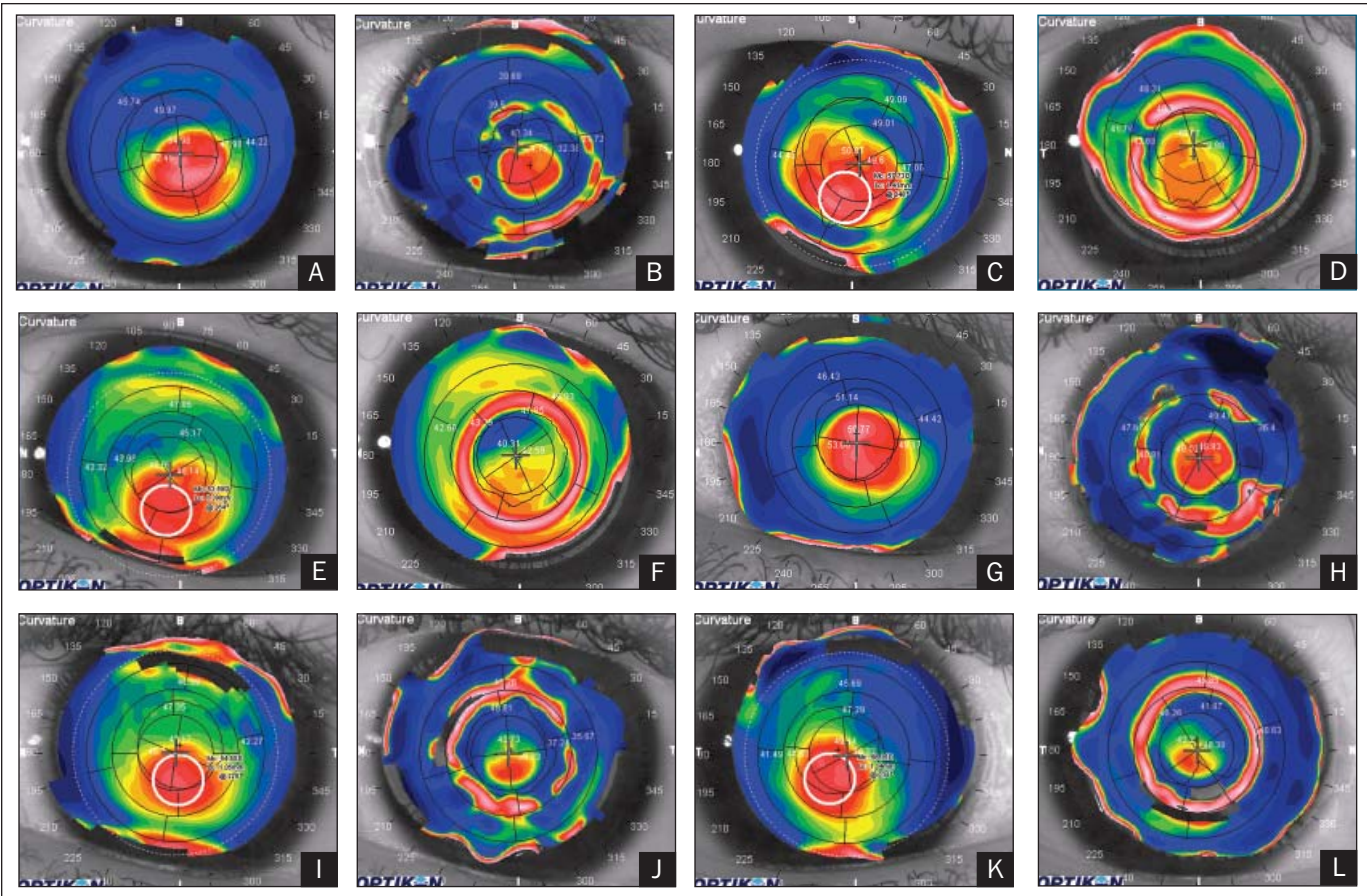


Figure 5. Preoperative and 6-month postoperative topography of each individual case in tangential maps—**A,B** case 1; **C,D** case 2; **E,F** case 3; **G,H** case 4; **I,J** case 5; and **K,L** case 6. Tangential mapping is superior to axial mapping in demonstrating the implant position (red ring in the postoperative images). The white numbers represent the keratometric values related to the 3-, 5-, and 7-mm zone, respectively.

enhanced biomechanical effect of the implant on the corneal shape resulting from the “hardening” of the tissue rather than the added induction of a significant change in refractive parameters.

Because keratoplasty is still regarded as the ultimate approach in the treatment of keratoconus, it may be interesting to compare the results of CISIS with data obtained from keratoplastic surgery.

One year after microkeratome-assisted lamellar keratoplasty for keratoconus,¹⁶ UDVA was shown to be better than 20/200 in 16% of patients and CDVA better than 20/40 in 88%, whereas best contact lens corrected visual acuity was 20/40 or better in all patients. No significant change in 1-year values was observed during later postoperative examinations.

Eighty-seven percent of patients treated by penetrating keratoplasty for keratoconus achieved CDVA of 20/40 or better after 18 months.¹⁷ The residual mean spherical component of the refractive error was -4.09 D, residual mean cylinder was 2.67 D, and at least one episode of graft rejection occurred in 17.8% of cases. A comparison

of penetrating keratoplasty and Intacs revealed that treatment of keratoconus with Intacs is superior.¹⁸

All of these considerations raise the question whether keratoplasty can be replaced by intracorneal implants in combination with corneal CXL¹⁹ in the future treatment of keratoconus. Such a replacement may significantly reduce the rate of complications as well as the period of discomfort and recovery time for the patient.

The corneal intrastromal implantation system provides a new option for keratoconus management. The technique appears to be safe, effective in decreasing myopia, corneal steepness, and decentration of the corneal apex, and is also potentially reversible. In addition, CISIS can be combined with CXL.

AUTHOR CONTRIBUTIONS

Study concept and design (A.D.); data collection (H.M., R.S.V., A.D.); interpretation and analysis of data (A.D.); drafting of the manuscript (A.D.); critical revision of the manuscript (H.M., R.S.V., A.D.); statistical expertise (A.D.); administrative, technical, or material support (A.D.); supervision (A.D.)

REFERENCES

1. Krachmer JH, Feder RS, Belin MW. Keratoconus and related non-inflammatory corneal thinning disorders. *Surv Ophthalmol.* 1984;28:293-322.
2. Daxer A, Fratzl P. Collagen fibril orientation in the human corneal stroma and its implication in keratoconus. *Invest Ophthalmol Vis Sci.* 1997;38:121-129.
3. Colin J, Cochener B, Savary G, Malet F. Correcting keratoconus with intracorneal rings. *J Cataract Refract Surg.* 2000;26:1117-1122.
4. Alió JL, Shabayek MH, Artola A. Intracorneal ring segments for keratoconus correction: long-term follow-up. *J Cataract Refract Surg.* 2006;32:978-985.
5. Alió JL, Artola A, Hassanein A, Haroun H, Galal A. One or 2 Intacs segments for the correction of keratoconus. *J Cataract Refract Surg.* 2005;31:943-953.
6. Alió JL, Shabayek MH. Intracorneal asymmetrical rings for keratoconus: where should the thicker segment be implanted? *J Refract Surg.* 2006;22:307-309.
7. Boxer Wachler BS, Christie JP, Chandra NS, Chon B, Korn T, Nepomuceno R. Intacs for keratoconus. *Ophthalmology.* 2003;110:1031-1040. Erratum in *Ophthalmology.* 2003;110:1475.
8. Sharma M, Boxer Wachler BS. Comparison of single-segment and double-segment Intacs for keratoconus and post-LASIK ectasia. *Am J Ophthalmol.* 2006;141:891-895.
9. Shetty R, Kurian M, Anand D, Mhaske P, Narayana KM, Shetty BK. Intacs in advanced keratoconus. *Cornea.* 2008;27:1022-1029.
10. Shabayek MH, Alió JL. Intrastromal corneal ring segment implantation by femtosecond laser for keratoconus correction. *Ophthalmology.* 2007;114:1643-1652.
11. Siganos D, Ferrara P, Chatzinikolas K, Bessis N, Papastergiou G. Ferrara intrastromal corneal rings for the correction of keratoconus. *J Cataract Refract Surg.* 2002;28:1947-1951.
12. Daxer A. Corneal intrastromal implantation surgery for the treatment of moderate and high myopia. *J Cataract Refract Surg.* 2008;34:194-198.
13. Daxer A. Adjustable intracorneal ring in a lamellar pocket for keratoconus. *J Refract Surg.* Available at: <http://www.journalofrefractive-surgery.com/preprint.asp>. Posted online March 18, 2009.
14. Raiskup-Wolf F, Hoyer A, Spoerl E, Pillunat LE. Collagen crosslinking with riboflavin and ultraviolet-A light in keratoconus: long term results. *J Cataract Refract Surg.* 2008;34:796-801.
15. Grewal DS, Brar GS, Jain R, Sood V, Singla M, Grewal SP. Corneal collagen crosslinking using riboflavin and ultraviolet-A light for keratoconus: one-year analysis using Scheimpflug imaging. *J Cataract Refract Surg.* 2009;35:425-432.
16. Busin M, Zambianchi L, Arffa RC. Microkeratome-assisted lamellar keratoplasty for the surgical treatment of keratoconus. *Ophthalmology.* 2005;112:987-997.
17. Brierly SC, Izquierdo L Jr, Mannis MJ. Penetrating keratoplasty for keratoconus. *Cornea.* 2000;19:329-332.
18. Rodriguez LA, Guillén PB, Benavides MA, Garcia L, Porras D, Daqui-Garay RM. Penetrating keratoplasty versus intrastromal corneal ring segments to correct bilateral corneal ectasia: preliminary study. *J Cataract Refract Surg.* 2007;33:488-496.
19. Wollensak G, Spoerl E, Seiler T. Riboflavin/ultraviolet-a-induced collagen crosslinking for the treatment of keratoconus. *Am J Ophthalmol.* 2003;135:620-627.